



Combating oral candidiasis in albino rats using bioactive fraction of *Acorus calamus*

Subha T.S* and Gnanamani A.

Microbiology Division, Central Leather Research Institute, Adyar, Chennai, Tamil Nadu, India 600 020

*Corresponding author email: subhatss@gmail.com

Published at www.biosciences.elewa.org on September 7, 2009

ABSTRACT

Objective: *Candida albicans* causes oral candidiasis (thrush) in immunocompromised individuals. The predisposing factors include a) Xerostomia; b) Antibiotic therapy; c) Poor oral or denture hygiene; d) Malnutrition/Gastrointestinal mal absorption; e) Iron, folic acid, or vitamin deficiencies; f) Acidic saliva/Carbohydrate-rich diets; g) Heavy smoking; and h) Oral epithelial dysplasia.

Combating these infections is cumbersome, as there is often recurrence. The existing conventional drugs pose several undesirable side effects. Hence there has been a continuous need for new drugs, especially the biocompatible and bio – based drugs. In earlier laboratory studies using methanolic extract of *Acorus calamus*, it was found that the active fraction of the methanolic extracts were able to control the biofilm formation of *Candida* spp. and more over the extracts were able to kill the biofilm cells to 100%. Biofilm formation is one of the pivotal factors in establishing the infections in the host. In the present study, an attempt was made to evaluate the effect of active fraction of the methanolic extract of *Acorus calamus* to combat oral candidiasis under *in vivo* conditions.

Methodology and results: Rhizomes of *Acorus calamus* was obtained from the medicinal farm of Dharmapuri, India. The rhizomes were shade dried and coarsely powdered. The methanolic extract obtained using the powder was further fractionated and the active fractions were used for this study. Oral Candidiasis model was created using Albino wistar rats. *Candida* isolates used for this study was isolated from patients suffering from oral candidiasis (SRMC). The invitro efficacy was already tested (results not shown) and hence the *in vivo* testing using albino rats model was executed. Infections was created in the oral cavity and left untreated for four days till the symptoms of the disease were well established. The rats were then treated with that of the Active fractions, Ketoconazole and Saline. The Microbial load was continuously assessed. Morphological, hematological and biochemical, histopathological, microbiological and SEM analyses revealed, that the evaluated plant based compound effectively controlled the oral candidiasis within a short period of time (5days) compared to positive control. The effectiveness of the active fraction was evaluated on the basis of the physical and microbiological examination. The study primarily focuses on the gradual reduction in microbial load from the infection site while treating with active fraction, conventional drug Ketoconazole, and Saline.

Conclusion and application of findings: From the studies it was found that the active fraction was able to control the infections under both invitro and invivo conditions. After further research the active fraction can be used as a potent drug to combat fungal infections.



Key words: Oral candidiasis, *Acorus calamus*, *Candida albicans*

INTRODUCTION

Candida albicans resides as commensal in the mucocutaneous cavities of skin, vagina, and intestine of humans and cause infections under altered physiological and pathological conditions such as infancy, pregnancy, diabetes, prolonged broad spectrum antibiotic administration, steroidal chemotherapy as well as AIDS. Oropharyngeal candidiasis is the most common infection associated with oral injuries (Kamai *et al.*, 2001). The expression of *Candida albicans* virulence in the oral cavity is strongly correlated with impairment of the immune system, particularly in patients with human immunodeficiency virus infection. *Candida albicans* spreads throughout the body and may sometimes affect the brain.

Candida sp. disrupts the endocrine system and cause symptoms like thrush, white coating on tongue, menstrual irregularities, joint pains, asthma, high fever, sinusitis, weight gain or loss and ear infections. *C. parapsilosis*, *C. tropicalis*, *C. krusei*, *C. glabrata*, *C. guilliermondii* and more recently *C. dubliniensis* are the species dominating in oral infections (Coleman *et al.*, 1997). The pathogenicity lies with their adherence capacity, colonization, enzyme production and interactions with host defences (Samaranayake, 1990).

The antifungal drugs commonly used to treat candidiasis are *nystain*, *avuconazole*, *clotrimazole*, *fluconazole* and *ketoconazole* (Kauffman & Carver 1997, Masci, 2000, Clemons & Stevans, 2001). In recent years, polyenes and azole agents have been used for treating infections caused by *C. albicans*.

MATERIALS AND METHODS

Organism: Therapeutic efficacy studies were performed against *Candida albicans* (CLCA 0510). The strain was obtained from an oral thrush patient from SRMC, Chennai, India. The culture was stored at -20° C in Sabouraud dextrose broth containing 15% glycerol until use. For inoculation, *C. albicans* CLCA0510 was grown on Sabouraud

Natural plant products have also been used since ancient times, but the recent recurrent infections have revived interest in the products. Some plant essential oils are known to have various health benefits, especially antifungal, antibacterial, anti-inflammatory and antioxidative properties (Chami *et al.*, 2004). The lack of scientific validation of their use as preventive and therapeutic products restricts their application in human health.

In oral candidiasis, herbal formulations and phytotherapies (Hammer *et al.*, 1999; Manohar *et al.*, 2001; Kalemba & Kunicka 2003) play a major role. *Punica granatum* Linn. exhibits an immense therapeutic value as antitumour, antibacterial and antifungal agent (Mohammad, 2005). *Aloe vera* has been used around dental implants to control inflammation from bacterial contamination, in addition to controlling other oral disorders, candidiasis, hematological and nutritional disorders. The phenolic major components of oregano and clove oils have been reported to treat diseases caused by *C. albicans* more effectively compared to synthetic drugs. Further, the potential of lactoferrin (LF), a multifunctional milk protein, for treatment of oral candidiasis in immunosuppressed mice has been reported by Natsuko *et al.*, (2003).

In the present study, we carried out animal experiments to assess the effect of active fractions of *Acorus calamus*, a traditional medicinal plant in controlling oral candidiasis.

dextrose agar (Himedia, India) plates at 30°C for 24 h. Fungal colonies were then scraped off the agar, washed three times in Phosphate Buffered Saline (PBS; pH 7) and solution was adjusted to appropriate concentration using haemocytometer.

Antifungal drugs: Rhizomes of *Acorus calamus* L. were obtained from medicinal farms in South



India, and a voucher specimen was deposited in Plant anatomy research centre, Chennai. The crude methanolic extract was fractionated using column chromatography and the active fractions 1 and 2 were used for the study. Ketoconazole, Amphotericin B, were also used as representatives of standard drugs.

Animals: The whole experimental plan was approved by CLRI ethical committee (Ref No:466/01/a/CPCSEA/2001; IAEC/06/001/07). Six-week-old, specific-pathogen-free, male and female Wistar strain rats weighing approximately 200 g each were used. The rats were housed in 480x270x200 mm APEC cages on corncob granules. Photoperiods were adjusted to 12/12 h light and darkness cycle daily, and the environmental temperature was constantly maintained at $21 \pm 1^\circ\text{C}$. Access to food and water was allowed *ad libitum* to rats.

Oral candidiasis model: Prior to infection, all the test animals were pre-checked for any pre-existing candidiasis using sterile swabs rolled in the buccal cavity followed by a lawn on hi-chrome agar medium. Oral infection was induced basically as reported by Jones and Adams (1970), with some modifications. Seven days prior to infection, rats were immuno-suppressed by administering dexamethasone in drinking water at a dose of 0.5 mg per litre in addition to 0.1% of aqueous solution of tetracycline hydrochloride. The concentration of tetracycline hydrochloride was reduced to 0.01% when the infection process started and maintained throughout the experiment. Experimental infection was established by rolling of cotton swab immersed in *Candida albicans* CLCA0510 suspension containing 5×10^8 cells in the oral cavities of rat three times at 48-h intervals. Rats were then randomly distributed into groups of 6 animals each ($n=6$). Three days after the last *Candida* inoculation, infected animals were identified by quantifying the number of CFU in the oral cavity as per the procedure summarized below. The mean \log_{10} CFU and standard deviation per sample were calculated and used as the basal level of infection before treatment.

Experimental groups: Each group had 6 animals, grouped as Group 1: healthy; Group 2: treated with standard drug Ketoconazole; Group 3: treated with active fraction 1 of *Acorus calamus* (AF1); Group 4; treated with active fraction 2 of *Acorus calamus* (AF2); and Group 5: infected.

Evaluation of severity of infections: At the end point of infection evaluation (after 7 days), animals were sacrificed under anaesthesia and the severities of tongue lesions were evaluated. Macroscopic evaluation of the infection was indicated by a lesion score from 0 to 4 on the basis of the extent and severity of whitish, curd-like patches on the tongue surface as follows: 0= normal; 1 = white patches over less than 20%; 2 = white patches over less than 90% but more than 21%; 3 = white patches over more than 91%; 4 = thick white patches like pseudo membranes over more than 91% of the tongue.

To assess the microbiological progression of infection the whole oral cavity, including buccal mucosa, tongue, soft palate, and other oral mucosal surfaces, was swabbed with a sterile cotton pad. The end of the cotton pad was then cut off and placed in a tube containing 5 ml of sterile physiological saline. After mixing with a vortex mixer to release *Candida* cells from the swab into the saline, 100 μl of undiluted cell suspension or its 100-fold dilutions were plated and incubated on Sabouraud dextrose agar (SDA) plates at 37°C for 20 h and the CFU of *Candida* cells were counted.

Antifungal therapy: Antifungal therapy was started 4 days after the inoculation. Ketoconazole, active fraction AF1 and active fraction AF2 were administered as oral application at the dose of 10mg/kg weight of the rat. For this model, treatment was given once in 24 h for 5 consecutive days.

Microbiological evaluation of compound efficiency: The efficacy of the treatments was assessed by counting the colony forming units (CFU) of *C. albicans* and comparing to that of the infected groups. Oral samples were collected by rolling a sterile cotton swab, suspended in 1 ml of PBS and cultured on Sabouraud Dextrose agar.



After incubation, yeast count was expressed as \log_{10} CFU per millilitre.

Blood and serum analysis: After microbiological analysis, the animals were sacrificed and the blood drawn immediately and subjected to haematological analysis, which included measurement of (1) Haemoglobin; (2) Haematocrit (PCV); (3) Serum bilirubin; (4) Serum aspartate amino transferase (SGOT); (5) Serum alanine amino transferase (SGPT or ALT); (6) Plasma/serum electrolytes – sodium and potassium; (7) serum alkaline phosphatase; (8) serum creatinin; (9) Erythrocyte sedimentation rate (ESR); (10) Blood sugar and (11) Urine albumin.

Liver tissue - enzyme analyses: After blood withdrawal, the liver from the animals of each experimental groups was collected and subjected to Glutathione S-transferase (GST); Lipid peroxidase (LPO); Peroxidase; Catalase; Superoxide dismutase and glutathione reductase as per the standard protocols.

In brief, Glutathione s-transferase (GST) activity was measured by the method of Habig *et al.* (1974). The reaction mixture contained 1.425 ml phosphate buffer (0.1 M pH6.5), 0.2 ml GSH (1 mM), 0.025ml CDNB (1 mM), 0.3 ml and 0.05 ml of hepatic PMS (10%w/v), respectively, in a total volume of 2.0 ml. A change in absorbance was recorded at 340 nm and expressed as nmol CDNB conjugate formed/min/mg protein using a molar extinction coefficient of 9.63103 M/cm .

Lipid peroxidase assay (LPO) was performed in hepatic PMS by the methods of Wright *et al.* (1981). The reaction mixture in a total volume of 1.0 contains 0.58 ml phosphate buffer

(0.1M, pH 7.4), 0.2 ml of hepatic PMS (10%w/v), 0.2 ml ascorbic acid (100mM) and 0.02 ml ferric chloride (100mM) was incubated at 37°C in a shaking water bath for 1 hour. Addition of 1 ml trichloro acetic acid (TCA) (10%w/v) arrested the enzyme reaction. After this, 1 ml of thiobarbituric (TBA) (0.67%w/v) was added and all the tubes were placed in a boiling water bath for 20 min. The amount of malonaldehyde (MDA) formed in each of the samples was assessed by measuring the optical density of the supernatant at 535 nm. Catalase activity of liver tissue was assayed by the method of Claiburni (1985). The assay mixture consisted of 1.95 ml phosphate buffer (0.05 M, pH 7.0), 1 ml H_2O_2 (0.019 M), 0.05 ml of hepatic PMS (10% w/v). Changes in absorbance were recorded at 240 nm and expressed as nmol H_2O_2 consumed/min/mg protein. Peroxidase activity was assessed according to the method of Chance and Maehly (1955).

Superoxide dismutase (SOD) activity was measured according to the method of Marklund and Marklund (1947) using pyrogallol as the substrate and expressed as U/mg of protein. Glutathione reductase activity was assayed according to Mohandas *et al.* (1984) and expressed as nmol NADPH oxidized/min/mg protein using a molar extinction co-efficient of $6.22 \times 10^3 \text{ M/cm}$.

Histopathology: Neutral buffered formalin was used to preserve the tongue sections and then the tissues were embedded in paraffin. The embedded tissues were sectioned using microtome and stained with hematoxylin and eosin as described by Martinez *et al.* (2001).

RESULTS AND DISCUSSION

Therapeutic efficacies of active fractions of *Acorus calamus*, AF1 and AF2, in controlling oral candidiasis were evaluated by assessing the morphological changes in the tongue, microbiological examination on number of colony forming units in the lesions of buccal cavity, haematological examination of blood and biochemical analyses of liver tissue. The

procedure adopted in the present study exhibited a progressive increase in the number of colonies after inoculation, which demonstrated that infection was successful in the buccal cavity with the formation of white patches on the dorsal side of the tongue.

Takakura *et al.* (2002) reported that when mice are infected with *Candida* spp. a thick white



coating develops on the tongue with lesions indicating successful infection. Further, when comparing the infection rate with the physiological behaviour of the animals, we observed appreciable correlation between infection and the feed and water intake of animals. There was a gradual reduction in the intake of feed and water, at the end of seventh day (after infection) the reduction percentage was 28 and 52% when

compared to healthy control as 100%, and also the behavioural pattern of the rats observed was very passive and weary after infection. Figure 1 depicts the CFU of *C. albicans* for all the experimental group animals. The maximum CFU of 30 ± 5 was observed on day 7 irrespective to the experimental groups.

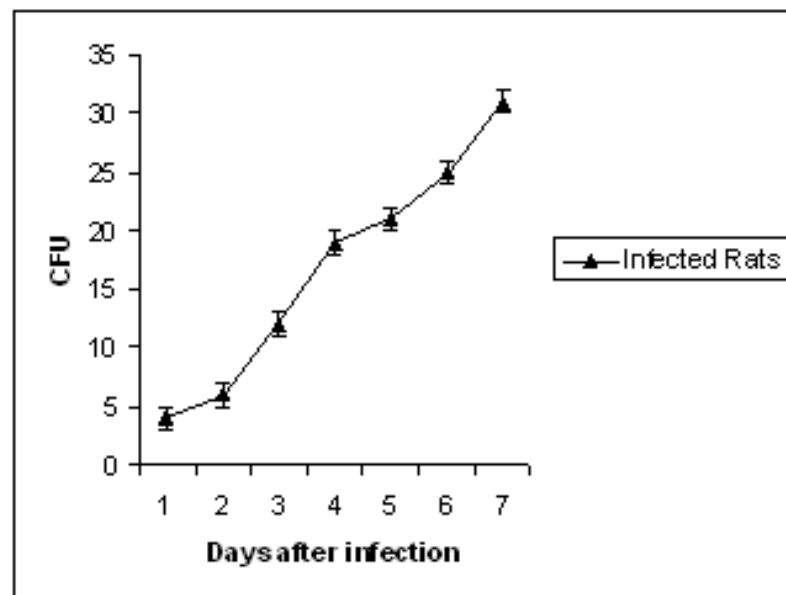


Figure 1: Colony forming units of *Candida albicans* CLCA0510 obtained after orally infecting rats.

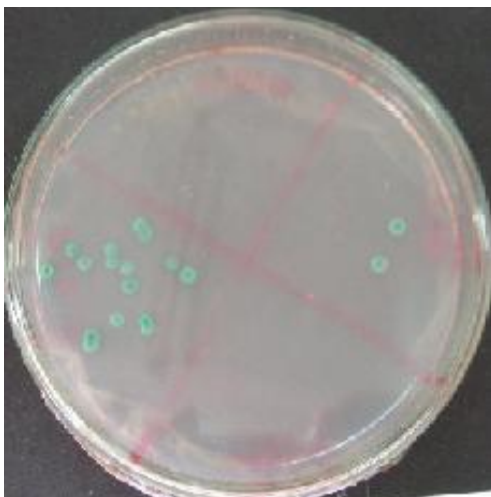


Figure 2a: *C. albicans* colonies on Hichrome agar.

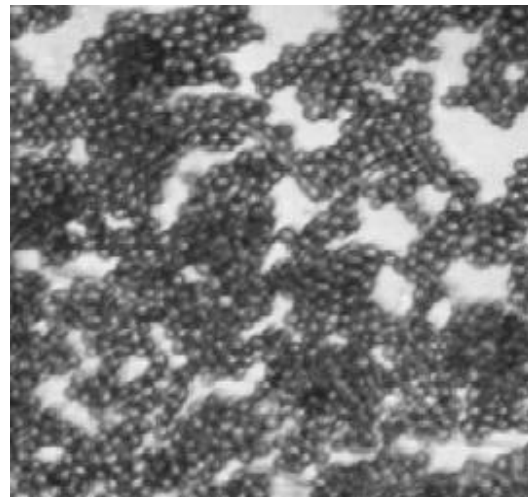


Figure 2b: Gram stained *C. albicans* cells.

Microbiological evaluation performed showed that no other bacterial or fungal contamination was present in the swab obtained. The growth of the organism in Hi-chrome agar plate (Figure 2a) and budding of yeasts (Figure 2b) showed the infection was successful. Therapeutic efficacy of the active fractions AF1 and AF2 of *Acorus calamus* was assessed on basis of reduction in CFU. The

results demonstrated a rapid decrease in the number of CFUs in the samples of groups treated with active fraction. About 99% reduction in fungal load was realised with AF1 and 98% with AF2 while the standard antifungal agent (Ketoconazole) treatment showed 95% reduction in load (Figure 3).

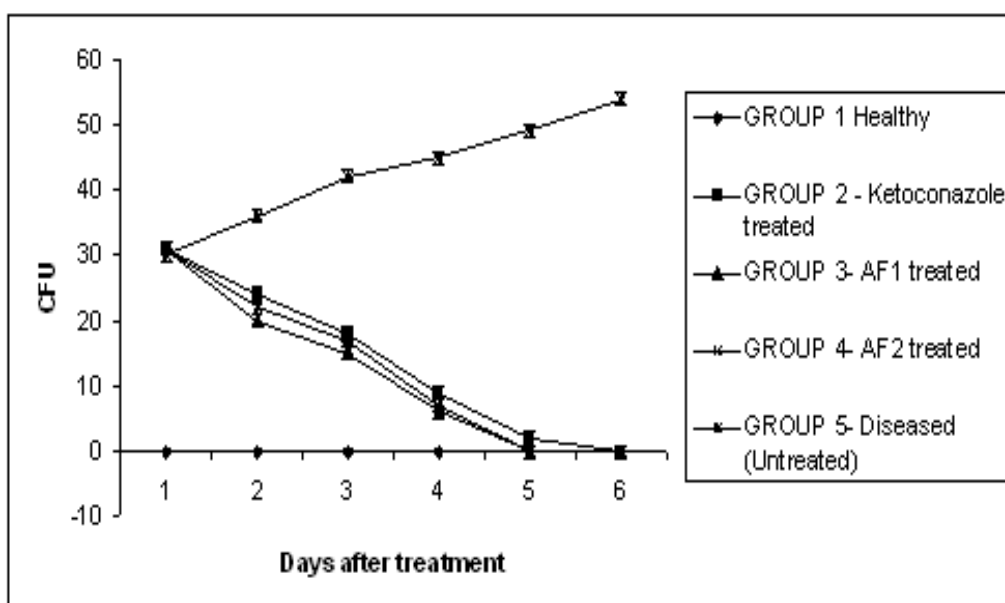


Figure 3: Colony forming units of *Candida albicans* CLCA0510 obtained from oral cavities of Wistar rats after treatment with active fractions of *Acorus calamus* and the standard drug ketoconazole.

Haematological study is a valuable diagnostic tool (Lee and Blaufox 1985). The haemoglobin content of blood of healthy animals lies in the range of 10-15 gms/dl. However, the infected animals (diseased) showed 22% less than the healthy control group; whereas the AF1 and AF2 treated animals showed 7% increase in haemoglobin content and 15% less compared to the healthy animals, respectively. Blood of animals treated with ketoconazole showed 20% less than the healthy group of animals (Table 1).

Bacterial or fungal infections affect the immunity level, which in turn affects the haemoglobin level in blood (Ashour *et al.*, 2007). Further, we observed a significant increase in the

Packed Cell Volume (PCV) in the case of rats treated with AF1, was much better than that of the healthy group, which shows that the compound in addition to being antifungal agents, also promotes the health of the animals. According to Ibekwe *et al.* (2007), the increase in the PCV was considered as indicating positive potential of the probiotics. They found that probiotic bacteria increased the PCV. Higher level of PCV was an indication that the rats were not anemic, while the lower limit as in the diseased control was more towards anemic condition (Table 1).

The WBC counts in AF1 was also slightly increased compared to that of the control. Erythrocyte Sedimentation Rate (ESR) analyses

often reflect the inflammatory response, and in the present study, an elevated ESR response levels were observed in the infected groups compared to the healthy and the treated group of animals (Table1). Further, we observed significant differences in the random blood sugar level between the healthy, treated and untreated groups of animals. The random sugar level in healthy animals was 27mgs/dl and 17 mgs/dl in those treated with ketoconazole. The sugar level was 18 and 16 mgs/dl for the samples from animals treated with AF1 and AF2, respectively.

The infected animals showed 11 mgs/dl of random blood sugar (Table1). With regard to Bilirubin content, no significant difference was detected between the healthy and those treated with AF1 and AF2. However, an increase in the level of bilirubin in the samples of infected animals was observed (Table1). An alkaline phosphatase level of 7.2 ± 1 ka was observed in all the groups except the infected animals. Alkaline phosphatase expression correlates with the infection rate, and in the present study we observed a level of 19 ± 2 for this parameter in the infected groups compared to 7.2 for the healthy groups. The treatment with AF1 and AF2 reduces the infection rate and maintains the alkaline phosphatase level under control. Similarly, SGOT and SGPT levels were elevated in the infected groups compared to the healthy and the treated groups (Table 1). We observed no significant difference in the sodium level between the infected, uninfected and the treated groups. However, significant difference were observed in the potassium level of the infected (5.5 ± 0.2 ppm), uninfected (2.6 ± 0.2 ppm), ketoconazole treated (4.7 ± 0.6 ppm) and AF1 and AF2 treated (2.4 ± 0.2 ppm) groups. The reason of increased potassium level in the infected groups is not known. The serum creatinine content showed 50% reduction in the infected groups compared to the uninfected and treated groups.

Urine analysis of infected, uninfected and treated groups revealed no significant difference in the colour and pH of the samples. However, the

samples of infected groups were positive for albumin and no albumin content was observed in the treated and the uninfected groups.

With regard to biochemical analysis of liver tissue (PMS), we observed the lowest level of expression of SOD in the samples from rats treated with standard drug compared to the uninfected, infected and those treated with AF1 and AF2 (Figure 4). With regard to catalase activity, the trend was similar to that of SOD. Reduction in catalase activity was observed with the groups treated with ketoconazole compared to the uninfected and those treated with AF1 and AF2. However, the infected groups exhibited the lowest level of catalase activity (Figure 5). The peroxidase level in the infected groups was zero, whereas in the uninfected groups it was in the range between 1.5-1.6 U/ml/mg of protein (Figure 4). However, the peroxidase level of those treated with ketoconazole was in the range of 1.0-1.1 U/ml/mg of protein, and in the range of 1.3-1.4 u/ml/mg of protein for rats treated with AF1 and 1.6-1.7 U/ml/mg of protein in those treated with AF2. The significant variation in the peroxidase level of infected and uninfected groups indicates damage of liver tissues in the infected groups (Figure 4).

Analysis of LPO in the form of malandialdehyde (MDA) of liver tissue revealed the release of MDA from the infected groups that was significantly higher than in the uninfected rats and the treated groups (Figure 6) Glutathione – S – transferase assay of liver tissue showed no significant difference in the infected, uninfected and treated groups, which implies that components of AF1 and AF2 are not carcinogenic. Further, glutathione reductase analysis of liver tissue showed significant variation in the rats treated with AF1 and AF2. This could be indicative that the components of AF1 have high antioxidant property, which is reflected in the higher glutathione reductase activity compared to AF2. The infected groups showed reduced level of glutathione reductase (Figure 4).



Table 1: Haematological profile of blood, serum and urine samples of infected, uninfected and treated groups of rats (N=6).

Parameters	Healthy control	ketokonazole	AF1	AF2	Untreated
Haemoglobin(gms/dl)	13±1	9.6±1	14±1	9.5±1	9.5±1
Haematocrit(PCV)	38±2	30±2	45±2	30±2	29±2
WBC (TC)cells/cu.mm	3050±25	3120±25	4080±25	2950±25	3950±25
Differential count of WBC's					
Neutrophils %	40±2	29±2	32±2	18±2	58±2
Eosinophils%	1	0	1	0	0
Basophils %	0	0	0	0	0
Lymphocytes %	58±2	72±2	66±2	70±2	40±2
Monocytes %	1	0	1	1	2
ESR end of 30 min (mm)	1	1	0	1	2
ESR end of 60 min (mm)	2	2	1	2	4
Random blood sugar (mgs/dl)	27±1	17±1	16±1	11±1	11±1
Bilirubin Test (mgs/dl)	0.4±0.1	0.4±0.1	0.4±0.1	0.4±0.1	0.4±0.1
Direct (mgs/dl)	0.3±.1	0.2±.1	0.3±0.1	0.2±0.1	0.3±0.1
In direct (mgs/dl)	0.1±.1	0.2±.1	0.2±0.1	0.2±0.1	0.2±0.1
Alkaline phosphatase (ka units)	7.53±1	7.2±1	7.0±1	7.2±1	19±1
SGOT/AST (U/L)	70±5	72±5	70±5	72±5	87±5
SGPT/ALT (U/L)	30±5	30±5	32±5	34±5	42±5
Sodium (meg/l)	110±10	115±10	101±10	108±10	112±10
Potassium (mgs/dl)	2.6±1	4.7±1	2.5±1	2.7±1	5.5±1
Serum creatinine (mgs/dl)	2±1	2.1±1	2±1	2±1	3.3±1
Urine Test					
Colour	Yellow	Yellow	Yellow	Yellow	yellow
pH	6.5	6.5	6.5	6.5	6.5
Albumin	Nil	Trace	Nil	Nil	4 plus

Figure 7 illustrates the microscopical examination of H& E staining of tongue sections obtained from the infected, uninfected, rats treated with AF1, AF2 and ketokonazole. The infected groups exhibited a complete loss of filiform papillae and the epithelium presented acanthosis and hyperplasia of the basal layer, with extensive formation of pseudohyphae and intraepithelial micro abscesses, with desquamation of the keratin in some areas. The healthy tongue showed the presence of filiform papillae. In the rest of the groups, i.e. those treated with standard

ketokonazole AF1 or AF2), there was a very mild difference in the structure of the filiform papillae, which could be resultant from the fungal attack. *C. albicans* can produce a broad variety of enzymes, such as proteinases, phospholipases and some hydrolytic enzymes that possibly produce destructive defects in the epithelial structures and components. However, in the treated tongue sections, there was rejuvenation of the papillae, which is considered to be a positive sign of recovery.

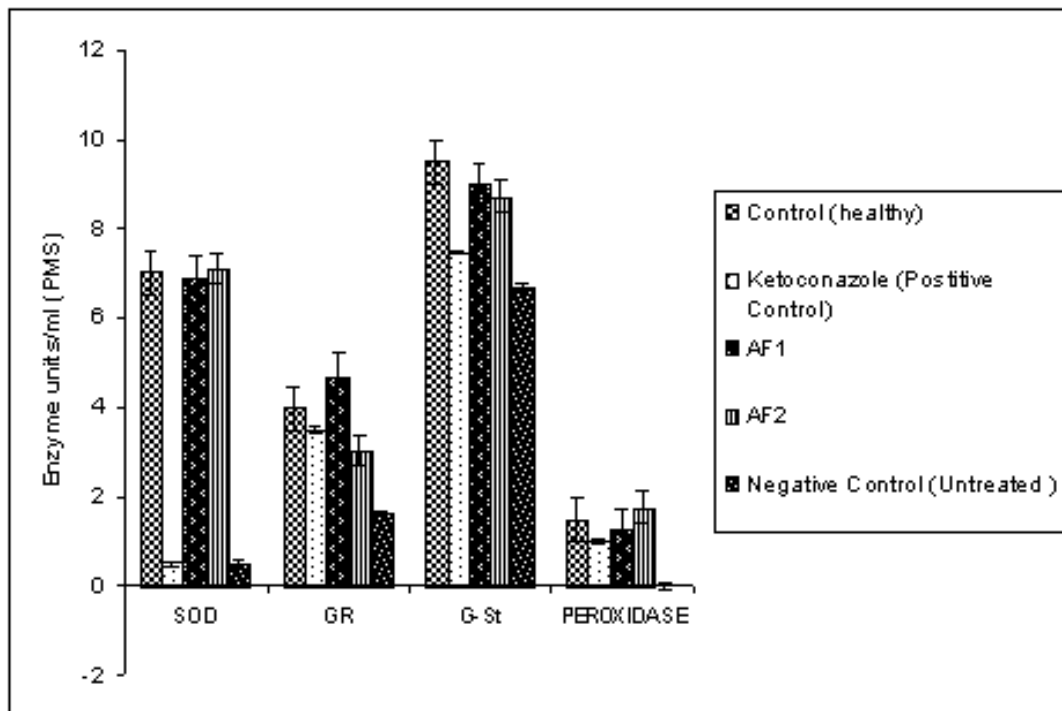


Figure 4: Superoxide dismutase, glutathione reductase, glutathione transferase, and peroxidase activity in liver PMS of rats inoculated with *Candida albicans* and treated with Active fractions 1 and 2 of methanolic extracts of *Acorus calamus* and Ketoconazole

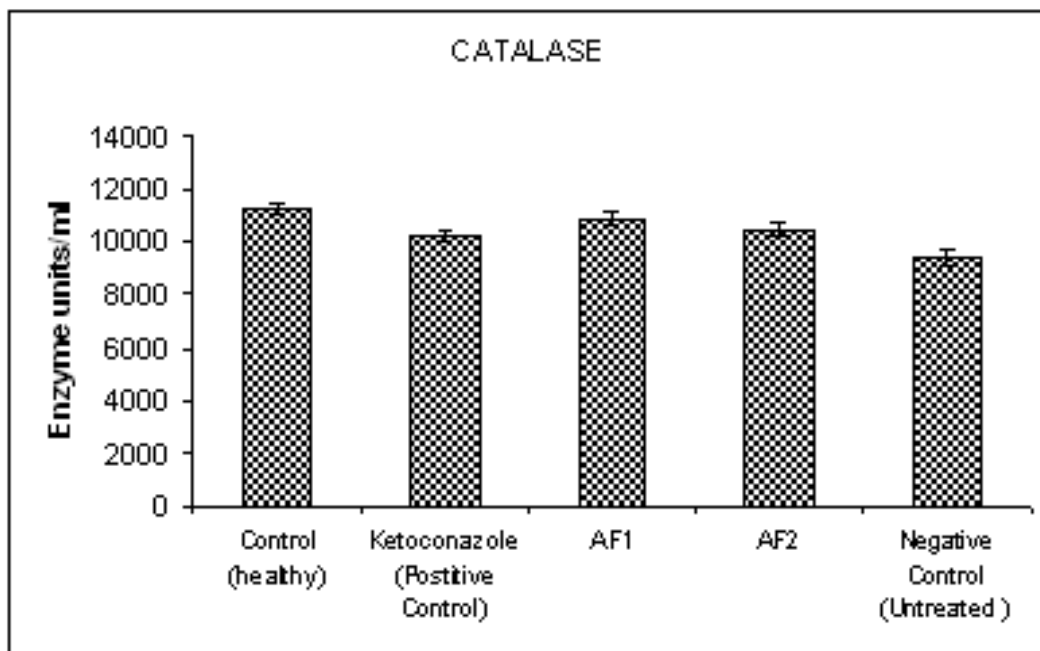


Figure 5: Catalase activities in the liver PMS of rats inoculated with *Candida albicans* and treated with Active fractions 1 and 2 of methanolic extracts of *Acorus calamus* and Ketoconazole



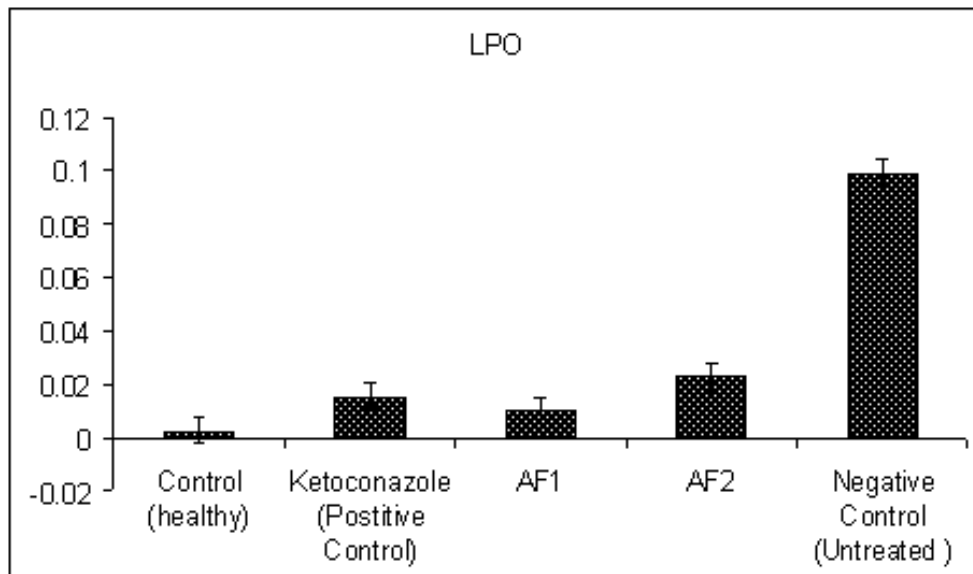


Figure 6: LPO activities in the liver PMS of rats inoculated with *Candida albicans* and treated with Active fractions 1 and 2 of methanolic extracts of *Acorus calamus* and Ketoconazole

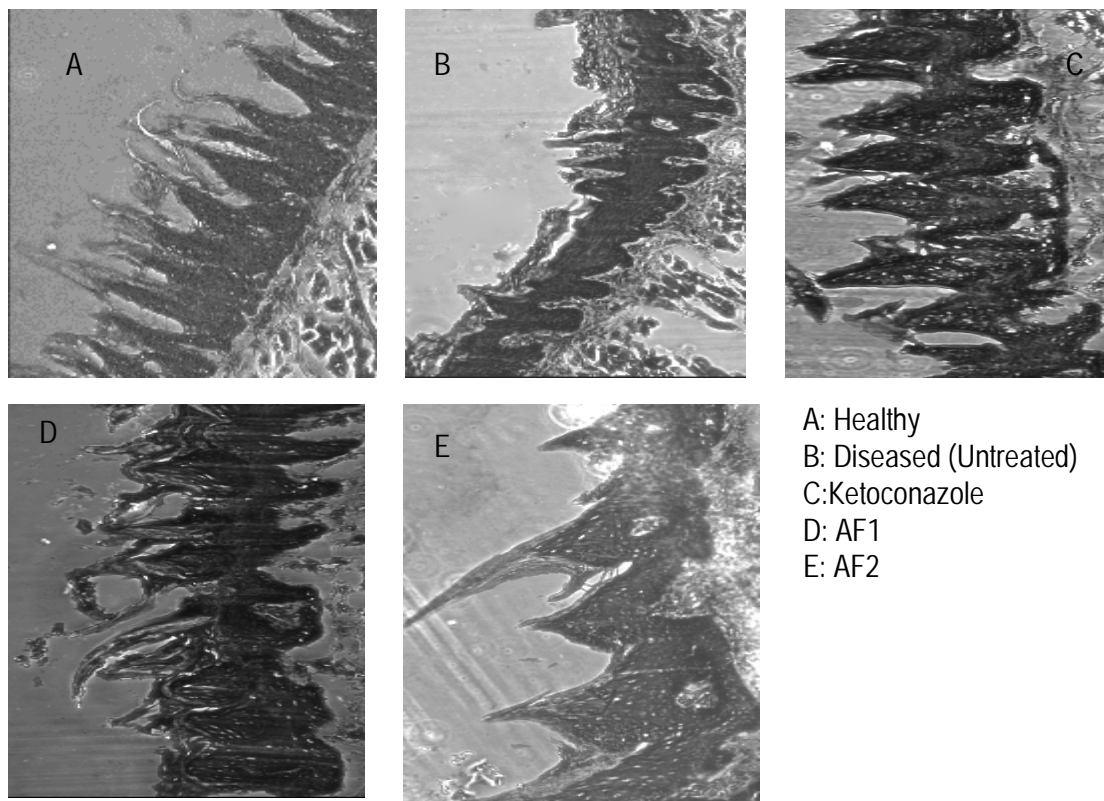


Figure 7: Histopathological sections of tongue of rats stained with Haematoxylin and Eosin after inoculated with *Candida albicans* and treated with Active fractions 1 and 2 of methanolic extracts of *Acorus calamus* and Ketoconazole.



CONCLUSION

The opportunistic fungus *Candida albicans* is a major cause of oral and oesophageal infections in immuno-compromised patients, individuals on drug therapy and those chronically ill. In addition, patients suffering from hyposalivation have an increased prevalence of oral candidiasis. In the present study, we evaluated the effects of two active fractions of *Acorus calamus* (AF1 And AF2) to control oral candidiasis in animal models. Anticandidal activity of the active fraction was assessed by macroscopical, microbiological, haematological, and biochemical analysis of

tongue, blood, urine and liver and histopathological examination of tongue.

Treatment with the active fraction of *Acorus calamus* (AF1 and AF2) reduce the infection at appreciable levels and the rats showed remarkable recovery from infection, compared to the infected control and the those treated with the standard drugs. The biochemical, hematological and histopathological analysis of treated groups further authenticates the antifungal property of the chosen AF1 and AF2.

REFERENCES

- Allen CM, 1994. Animal models of oral candidiasis. Oral Surg. Oral Med. Oral Pathol. 78:216-221.
- Ashour ARA, Yassin MM, Abu Assi NM, Ali RA, 2007. Blood ,Serum Glucose and Renal parameters in Lead-Loaded Albino rats and treatment with some chelating Agents and natural oils. Turk J Biol. :31: 25-34.
- Chance B. and Maehly AC, 1955. Methods enzymol II: 773-75.
- Claiborne A, 1985. Catalase activity. Handbook of methods of oxygen radical research Boca Raton, FL:CRC, 283-284.
- Clemons KV. and Stevens DA, 2000. Treatment of orogastrointestinal candidosis in SCID mice with fluconazole alone or in combination with recombinant granulocyte colony stimulating factor or interferon- γ . Med. Mycol. 38: 213-219.
- Clemons KV. and Stevens DA, 2001. Efficacy of ravuconazole in treatment of mucosal candidosis in SCID mice. Antimicrob. Agents Chemother. 45: 3433-3436.
- Coleman DC, Sullivan DJ, Bennett DE, 1997. Candidiasis: the emergence of a novel species, *Candida dubliniensis*. AIDS 11:557-567.
- Habig WH. and Jakoby WB, 1981. Methods enzymol: 77: 398-405. Haematological parameters of wistar albino rats. Scientific Research and Essay Vol. 2 (1): 2007: 006-009,
- Hammer KA, Carson CF, Riley TV, 1999. Antimicrobial activity of essential oils and other plant extracts. J App Microbiol. 86:985-990.
- Hermann SP, Berek Z, Nagy G, Skamatsay K, Rozgonyi F, 2001. Pathogenesis, microbiological and clinical aspects of oral candidiasis S(candidosis). Acta Microbial Immunol Hung 48: 479-495.
- Ibekwe, Eberechukwu S, Uwakwe, et al. Effect of oral intake of sodium benzoate on some
- Jones JC, Russell C, Young D. Owen, 1976. Tetracycline and the colonization and infection of the mouths of germs-free and conventionalized rats with *Candida albicans*. J.Antimicrob. Chemother. 2: 247-253.
- Kalemba D. and Kunicka A, 2003. Antibacterial and antifungal properties of essential oils. Curr Med Chem. 10(10)S: 813-829.
- Kamai Y, Kubota M, Fukuoka T, Filler SG, 2001. New model of oropharyngeal candidiasis in mice. Antimicrob. Agents Chemother. 45:3195-3197.
- Kauffman CA. and Carver PL, 1990. Antifungal agents in the 1990s. Current status and future developments. Drugs 53: 539-549.



- Lee HB. and Blaufox MD, 1985. Blood volume in Rats. *J. Nuci Med.* 25: 72-76.
- Manohar V, Ingram C, Gray J, 2001. Antifungal activities of origanum oil against *Candida albicans*. *Molecular and Cellular Biochemistry* 228:111-117.
- Marklund S. and Marklund G, 1974. Involvement of the Superoxide Anion Radical in the Autoxidation of Pyrogallol and a Convenient Assay for Superoxide Dismutase. *European.J Biochem.*:47 (3) 469-74.
- Martinez A, Regardra J, Jimenez E, 2001. Antifungal Effecacy of GM237354, a Sordarin Derivative, in Experimental Oral Candidiasis in Immunosuppressed Rats. *Antimicrob Agents Chemother.* 45:1008-13.
- Masci JR, 2000. Complete response of severe, refractory oral candidiasis to mouthwash containing lactoferrin and lysozyme. *AIDS* 14:2403-2404.
- Mohandas J, Marshall JJ, Duggin GG, Hovarth JS, Tiller D, 1987. Low activities of glutathione- related enzymes as factors in the genesis of urinary bladder cancer. *Cancer Res.* 44:5086-5091.
- Samaranayake LP. and MacFariane TW, 1990. Oral candidosis: an old disease in new guises. *AIDS Commentary, Dental update* january/February 1990.
- Takakura N, Sato Y, Ishibashi H, 2003. A novel murine model of oral candidiasis with local symptoms characteristic of oral thrush. *Mocrobiol Immunol.* 47:321-326.
- Wright JR, Colby HD, Miles PR, 1981. Cytosolic factors which affect microsomal lipid peroxidation in lung and liver *Arch Biochem Biophys.* 206(2):296-304.

